

Histology – Connective Tissue

HASPI Medical Anatomy & Physiology 04b

Activity

Background

Connective Tissue

Connective tissue is the most abundant tissue type in the body. It is not as dense as epithelial tissue, and is made up of cells, fibers, and extracellular components embedded in fluid. This structure allows connective tissue to provide ample support, while also staying pliable. Cells called fibroblasts are responsible for producing connective tissues. Blood, bone, cartilage, tendons, ligaments, adipose (fat), and lymph are all examples of connective tissue.

The extracellular portion of connective tissue primarily includes the following:

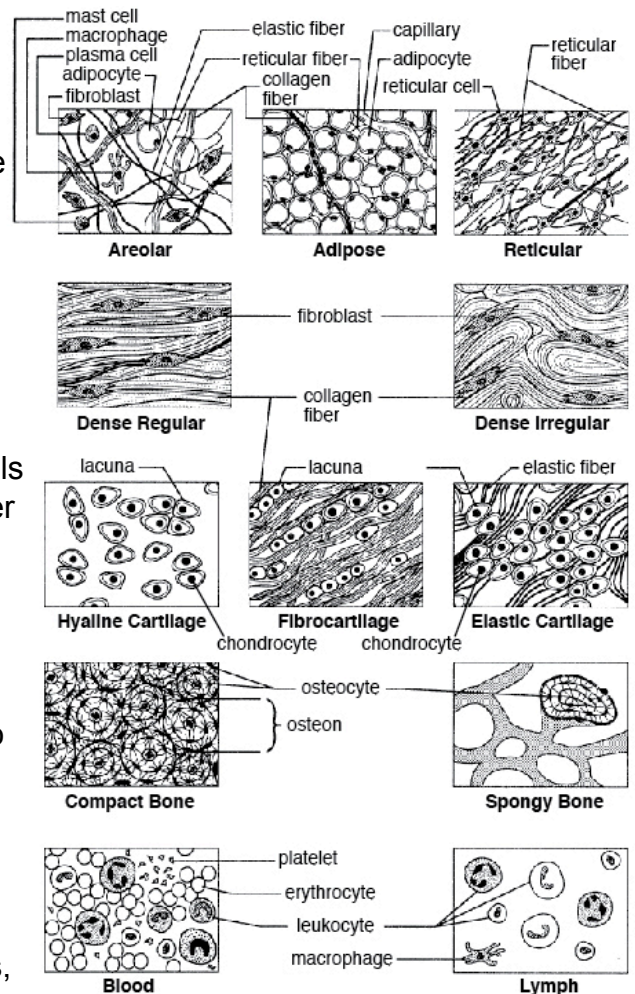
- Interstitial fluid – fluid that contains proteins and cells
- Adhesion proteins – allow cells to bind to each other and to structural fibers
- Proteoglycans – proteins that act to filter fluids through the ground substance
- Collagen – extremely strong fibers that provide support
- Elastin – fibers that are able to stretch and return to their original shape, much like a rubber band
- Reticular fibers – fine networking fibers

Connective tissue functions to protect, store energy, support, transport, insulate, and connect all body tissues. These tissues can be highly vascular, but can also be avascular, such as with cartilage. In the avascular tissues, they tend to be made up of more extracellular (non-living) matrices, or substances, rather than of cellular components.

Types of Connective Tissues

Name(s): _____

Period: _____ Date: _____

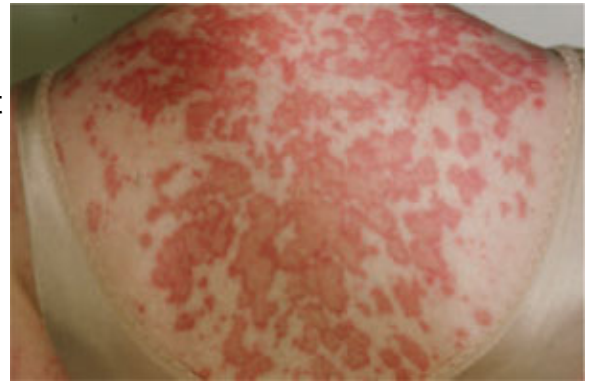


http://pharmaworld.pk.cws3.my-hosting-panel.com/products/stimg_43_344.jpg

Loose Connective Tissue	
Areolar	Binds cells and fibers together, but also allows movement
Adipose	Fat; stores nutrients, insulates, and protects organs
Reticular	Much like dense spider webbing; allows for structure and flow of substances
Dense Connective Tissue	
Regular	Make up tendon and ligaments; tightly organized bundles of collagen
Irregular	Make up the dermis; tight bundles of collagen that are unorganized
Cartilage	
Hyaline	Provides support while still being pliable; most abundant form of cartilage
Elastic	Provides support while still able to stretch
Fibrocartilage	Provides strong support and handles heavy pressure
Other Tissues	
Bone	Support; hard tissue of collagen fibers and calcium surrounding osteocytes
Blood	Tissue that contains red blood cells, proteins, and fluid called plasma

Connective Tissue Disorders & Disease

There are several diseases and disorders that specifically target connective tissues. Collagen and elastin are the most common components that are affected. These tissues may simply become injured through trauma, such as a sprain, or they may be caused by genetic or environmental factors. Often it is the body's own immune system that causes an inflammation in these tissues.



http://www.jfponline.org/images/5910/5910JFP_Article2-fig2.jpg

Symptoms tend to be disease-specific, but the most common symptoms associated with connective tissue disorders include fatigue, fever, muscle pain, stiffness, weakness, and joint pain. A few examples of connective tissue disorders include:

Disorder	What is it?	Symptoms	Prevalence
Ehlers-Danlos syndrome	Genetic disease that causes the deterioration of collagen	Fragile and stretchy skin, fatty lumps, extremely flexible joints	1 in 5,000
Marfan syndrome	Genetic disease that causes abnormal fibrillin production	Tall, slender, loose joints, disproportioned skeleton, scoliosis, dislocation of lens (eyes), cardiovascular disease, ectasia, less elastic alveoli	1 in 5,000
Osteogenesis imperfecta	AKA brittle bone disease; Insufficient collagen production, causing an inability to build bone structure	Short, bones easily fracture, blue sclera, deafness, scoliosis, kyphosis, bowed bones	1 in 20,000
Rheumatoid arthritis	Autoimmune disease that causes an inflammation of cartilage and joints	Swollen joints, joint pain, morning stiffness, firm bumps under skin, fatigue, weight loss, fever	9.8 in 1,000
Scleroderma	Autoimmune disease causing a build-up of scar tissue in the skin, blood vessels, and organs	Swelling, itching, tenderness of the skin, calcinosis, heartburn, Raynaud's phenomenon, increased blood pressure, renal crisis, bowel disease	1 in 906
Systemic lupus erythematosus	Inflammation of connective tissues	Varied; fever, fatigue, muscle ache, alopecia, arthritis, ulcers, photosensitivity, pleuritis, pericarditis, Raynaud's phenomenon	1 in 1,000

Shiel, W.C. and Stoppler, M.C. 2012. Connective Tissue Disease. www.medicinenet.com.

Materials

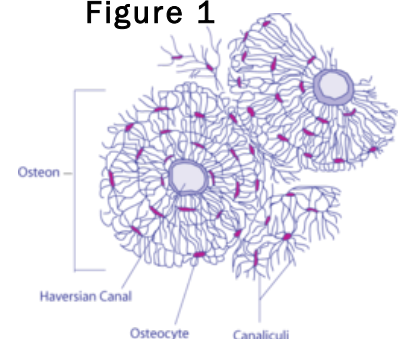
Connective tissue charts (12)
Computer/internet OR connective tissue slides and a microscope

Procedure

Part A. Becoming Familiar with Connective Tissues

In Part A of this lab you will have the opportunity to familiarize yourself with the different types of connective tissues. Posters with the 10 main types of tissues have been placed throughout the room. Visit each poster and record the description, function, and location in the following chart. Draw and label an example in the right column for each picture. An example drawing can be seen in Figure 1 to the right.

Figure 1



http://upload.wikimedia.org/wikipedia/commons/thumb/7/75/Transverse_Section_Of_Bone.png/250px-Transverse_Section_Of_Bone.png

a. Connective Tissue Proper: loose connective tissue, areolar

Description (write or draw)

Draw an example. Use colored pencils and label if necessary.

Function

Location

b. Connective Tissue Proper: loose connective tissue, adipose

Description (write or draw)

Draw an example. Use colored pencils and label if necessary.

Function

Location

c. Connective Tissue Proper: loose connective tissue, reticular

Description (write or draw)

Draw an example. Use colored pencils and label if necessary.

Function

Location

d. Connective Tissue Proper: dense connective tissue, dense regular

Description (write or draw)

Draw an example. Use colored pencils and label if necessary.

Function

Location

e. Connective Tissue Proper: dense connective tissue, dense irregular

Description (write or draw)

Draw an example. Use colored pencils and label if necessary.

Function

Location

f. Cartilage: hyaline

Description (write or draw)

Draw an example. Use colored pencils and label if necessary.

Function

Location

g. Cartilage: elastic

Description (write or draw)

Draw an example. Use colored pencils and label if necessary.

Function

Location

h. Cartilage: fibrocartilage

Description (write or draw)

Draw an example. Use colored pencils and label if necessary.

Function

Location

i. Others: compact bone (osseous tissue)

Description (write or draw)

Draw an example. Use colored pencils and label if necessary.

Function

Location

j. Others: blood

Description (write or draw)

Draw an example. Use colored pencils and label if necessary.

Function

Location

k. Others: spongy bone

Description (write or draw)

Draw an example. Use colored pencils and label if necessary.

Function

Location

l. Others: lymph

Description (write or draw)

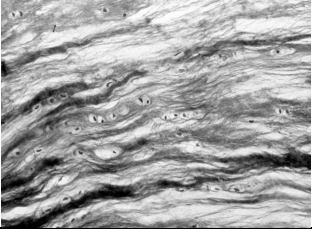
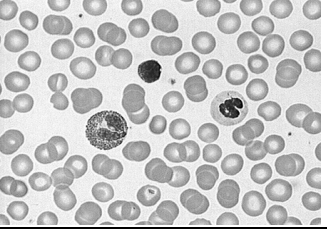
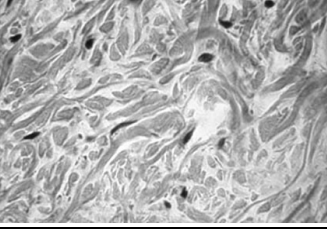

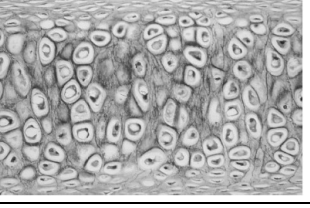
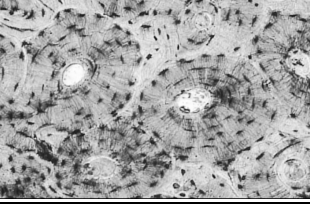
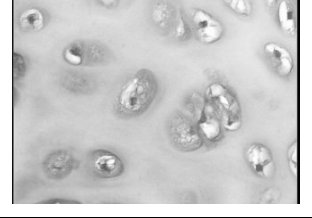
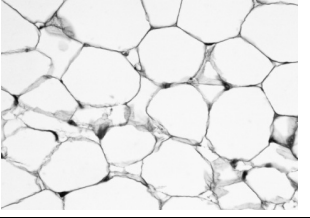
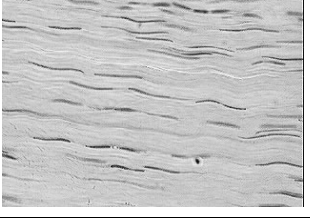
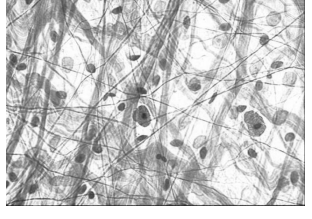
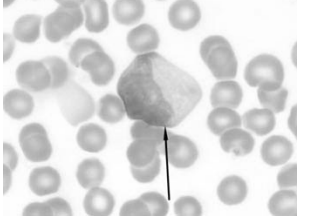
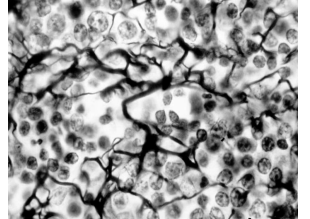
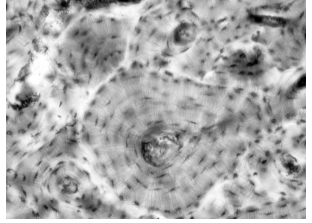
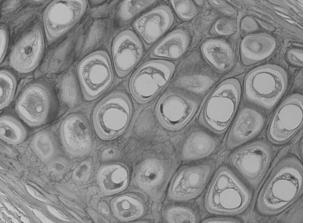
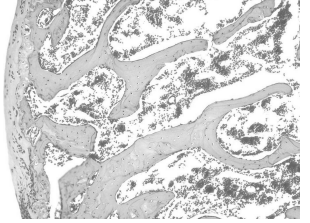
Draw an example. Use colored pencils and label if necessary.

Function

Location

Part B. Identify the Connective Tissue

In Part B of this activity, use what you have just learned to identify the following connective tissues. Write your answers on the line in each box.

<p>A. _____</p> 	<p>B. _____</p> 	<p>C. _____</p> 
<p>D. _____</p> 	<p>E. _____</p> 	<p>F. _____</p> 
<p>G. _____</p> 	<p>H. _____</p> 	<p>I. _____</p> 
<p>J. _____</p> 	<p>K. _____</p> 	<p>L. _____</p> 
<p>M. _____</p> 	<p>N. _____</p> 	<p>O. _____</p> 

- A. http://www.stegen.k12.mo.us/tchrpges/sghs/ksulkowski/images/39_Fibrocartilage_Connective_Tissue.jpg
 B. <http://lifesci.rutgers.edu/~babiartz/Histo/Blood/Smear1.jpg>
 C. <http://medicine2.keele.ac.uk/anatomy/histologyimages/t19.jpg>
 D. http://www.jeremyswan.com/anatomy/203/lab_03_tissues/Areolar-ct.jpg
 E. http://classconnection.s3.amazonaws.com/100/flashcards/1151100/png/elastic_cartilage_connective_tissue_31328663923618.png
 F. http://www.gwc.maricopa.edu/class/bio201/Histology/24Bone1_100X_rev.jpg
 G. <http://academics.eckerd.edu/instructor/denisosh/hyalinecart.jpg>
 H. http://imgc.artprintimages.com/images/art-print/gladdden-willis-human-unilocular-or-white-fat-adipose-tissue-h-e-stain-lm-x100_i-G-64-6473-HCQH100Z.jpg
 I. http://dtc.pima.edu/blc/160Mars/160Mimages/Dense_connectivex.jpg
 J. <http://www.newarkcolleges.com/kponto/AreolarConnectiveTissueSkin.jpg>
 K. <http://www.wadsworth.org/chemheme/heme/glass/cytopix/slide007atyp1.jpg>
 L. http://www.stegen.k12.mo.us/tchrpges/sghs/ksulkowski/images/32_Reticular_Connective_Tissue.jpg
 M. <http://www.vetmed.vt.edu/education/curriculum/vm8054/labs/lab8/IMAGES/OSTEON%20AND%20INTERSTITIAL%20SYSTEM.jpg>
 N. <http://www2.sunysuffolk.edu/pickenc/Elastic%20Cartilage%20400X.JPG>
 O. http://medcell.med.yale.edu/histology/bone_lab/images/trabecular_bone.jpg

Part C. Practice, Practice, Practice

Your instructor will either have slides available to view with the microscope OR you can use a computer and the following website to choose slides to view:

http://medsci.indiana.edu/c602web/602/c602web/virtual_nrml/nrml_1st.htm

For each type of connective tissue, observe the slide and identify the connective tissue.

- REMEMBER there are multiple tissue types on many of the slides.
- Start by searching through the slide for images similar to those in your drawings from Part A.
- You may need to move the slide around to find a good example!
- You may need to look up/research the organ function if it is unfamiliar.

a. Connective tissue proper: loose connective tissue, areolar

Slide Choices: areolar tissue slide, under epithelium, mucous membranes, surrounding capillaries

Organ

Draw an example. Use colored pencils.

Organ Function

Tissue Function

b. Connective tissue proper: loose connective tissue, adipose

Slide Choices: Fat or adipose slide, under skin, around kidneys, around eye, breast, abdomen

Organ

Draw an example. Use colored pencils.

Organ Function

Tissue Function

c. Connective tissue proper: loose connective tissue, reticular

Slide Choices: Reticular tissue slide, lymph nodes, bone marrow, spleen

Organ

Draw an example. Use colored pencils.

Organ Function

Tissue Function

d. Connective tissue proper: dense connective tissue, dense regular

Slide Choices: Dense regular tissue slide, tendons, ligaments, aponeuroses

Organ

Draw an example. Use colored pencils.

Organ Function

Tissue Function

e. Connective tissue proper: dense connective tissue, dense irregular

Slide Choices: Dense irregular tissue slide, dermis, submucosa, joint capsules

Organ

Draw an example. Use colored pencils.

Organ Function

Tissue Function

f. Cartilage: hyaline**Slide Choices:** Hyaline cartilage, embryo skeleton, end of long bones, costal cartilage, nose, trachea, larynx

Organ

Draw an example. Use colored pencils.

Organ Function

Tissue Function

g. Cartilage: elastic**Slide Choices:** Elastic cartilage, ear, epiglottis

Organ

Draw an example. Use colored pencils.

Organ Function

Tissue Function

h. Cartilage: fibrocartilage**Slide Choices:** Fibrocartilage, intervertebral discs, knee joint, pubic symphysis

Organ

Draw an example. Use colored pencils.

Organ Function

Tissue Function

i. Others: compact bone (osseous tissue)

Slide Choices: Bone

Organ

Draw an example. Use colored pencils.

Organ Function

Tissue Function

j. Others: blood

Slide Choices: Blood, red blood cell smear

Organ

Draw an example. Use colored pencils.

Organ Function

Tissue Function

k. Others: spongy bone

Slide Choices: Spongy bone

Organ

Draw an example. Use colored pencils.

Organ Function

Tissue Function

I. Others: lymph

Slide Choices: Blood, bone marrow, lymph

Organ	<i>Draw an example. Use colored pencils.</i>
Organ Function	
Tissue Function	

Analysis Questions - on a separate sheet of paper complete the following

1. Create a concept map titled "Connective Tissues" with a short description OR a drawn example including ALL of the following: *loose connective tissue, dense connective tissue, areolar tissue, adipose tissue, reticular tissue, regular dense tissue, irregular dense tissue, cartilage, hyaline cartilage, elastic cartilage, fibrocartilage, other tissues, compact bone, spongy bone, blood, and lymph.*
2. What is the difference between loose and dense connective tissue?
3. What is the difference between areolar, adipose, and reticular tissue?
4. What is the difference between regular and irregular dense tissue?
5. What is the difference between hyaline, elastic, and fibrocartilage?
6. What is the difference between compact and spongy bone?
7. **CONCLUSION:** In 1-2 paragraphs summarize the procedure and results of this lab.

Review Questions - on a separate sheet of paper complete the following

1. What three parts primarily make up connective tissue?
2. What are fibroblasts?
3. What parts of the body are classified as connective tissue?
4. What is interstitial fluid?
5. What are adhesion proteins?
6. What are proteoglycans?
7. What is the difference between collagen, elastin, and reticular fibers?
8. What is the function of connective tissues?
9. What is the difference between vascular and avascular tissue?
10. Create a chart with a description, function, and location of all of the loose and dense connective tissue types.
11. What components of connective tissue are most commonly affected by disease and/or disorder?
12. Out of the disorders listed in the chart in the background section, which connective tissue disorder is the most prevalent?
13. Choose one of those disorders and provide a description and the symptoms.