

ECG Activity

HASPI Medical Anatomy & Physiology 13c

Lab Activity

Background

Name(s): _____

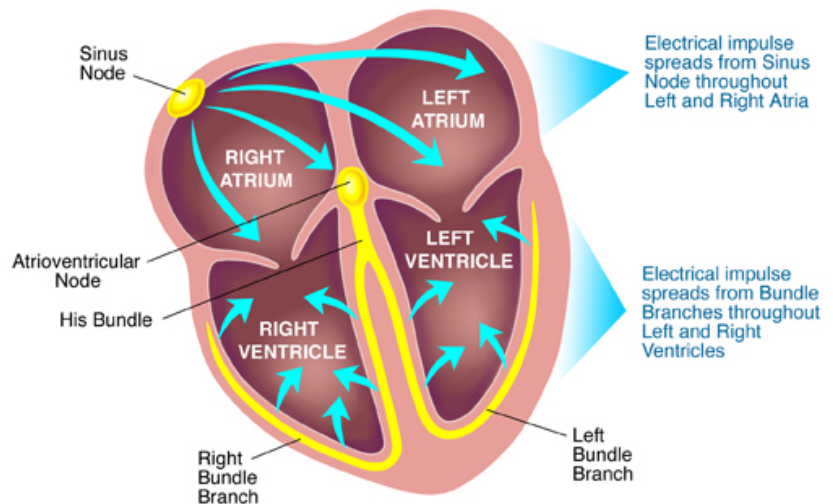
Period: _____ Date: _____

Cardiac Conduction

The heart has its own system in place to create nerve impulses and does not actually require the brain to make it beat. This electrical system is called the cardiac conduction system. It is made up of specialized tissues and cells embedded in the heart that send impulses directly to the atria and ventricles, causing them to contract. In the normal cardiac cycle, the left and right atria contract together first followed by the contraction of the ventricles together.

The cardiac conduction system is complex, but there are three crucial parts:

- The **Sinoatrial (SA) Node**
Also known as the pacemaker; this is a small bundle of cells capable of starting the electrical impulse that will cause the heart to beat.
- The **Atrioventricular (AV) Node**
A small bundle of cells that can receive the electrical impulse from the SA node, and continue the electrical signal down into the ventricles.
- **His-Purkinje System**
These fibers actually carry the electrical impulse to the ventricles, causing a contraction. The impulse starts at the His bundle fibers, continues into the right bundle branch and left bundle branch, and ends in Purkinje fibers spread throughout the ventricles.



<http://2.bp.blogspot.com/-rYtanZ5CjBE/T54xh0eE5OI/AAAAAAAAADM/tRYbXfTnGzMs1600/Control-of-heart-by-heart-conduction-system.jpg>

The Heartbeat

The sinoatrial (SA) node begins the contraction by sending an impulse through both atria, causing them to contract and reach the atrioventricular (AV) node. The AV node continues the impulse, sending it down the Bundle of His, right and left bundle branches, and into Purkinje fibers within the ventricles causing both ventricles to contract.

As the impulse moves through the heart, cardiac muscle tissue contracts as the cells depolarize. Depolarization is caused by a flood of ions (sodium and potassium) across the cell membrane and drives the cells, and therefore cardiac muscle tissues, to contract. Once the impulse has passed, the cardiac cells must reset to be able to send another impulse. This is called repolarization and occurs when the ions move back through the cell membrane, causing the cardiac muscle tissue to relax.

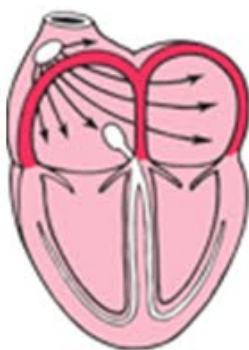
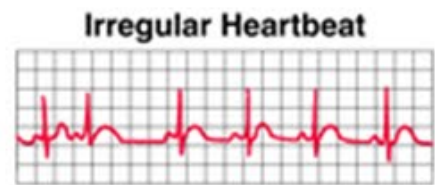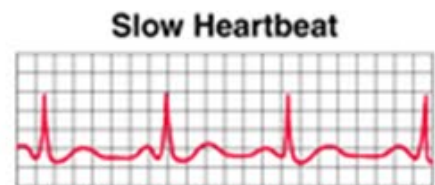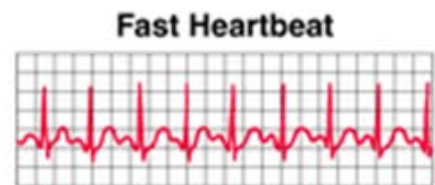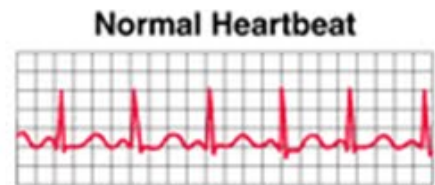
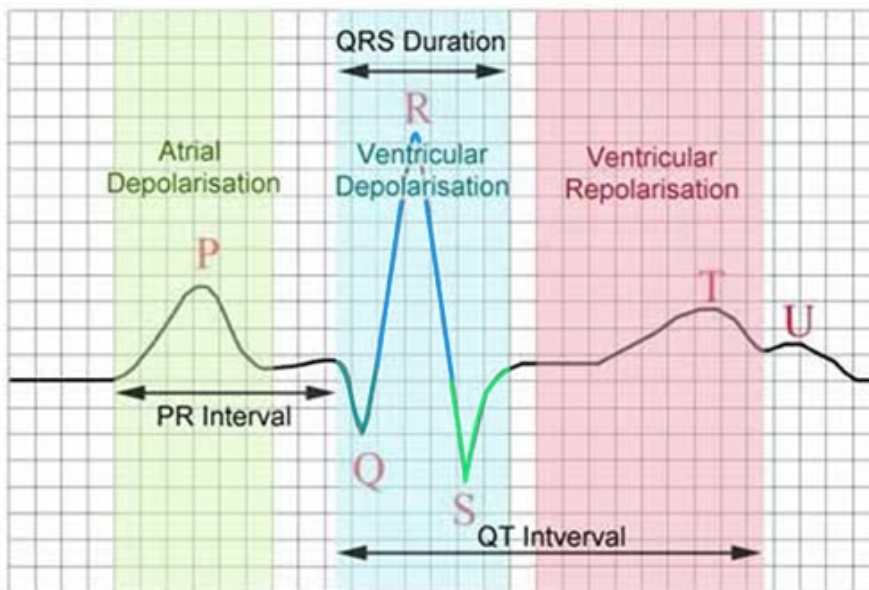
The SA node will create anywhere from 60-100 electrical impulses per minute. Each of these impulses causes your heart to beat and translates to your heart rate. The electrical impulse causes the heart to depolarize and contract, followed by repolarization and relaxation, at a constant rate. The normal rhythm and rate is called the sinus rhythm. The cardiac conduction system is also capable of increasing or decreasing the number of electrical impulses depending on the amount of oxygen needed by the body. For example, when you run a mile your need for energy increases, causing the need for more oxygen, and resulting in an increase in the heartbeat and respiratory rate to bring more oxygen into the body.

Electrocardiograms

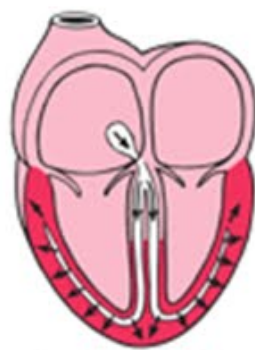
An electrocardiogram is a measurement of the electrical activity and impulses created by the heart. It is most often referred to as an EKG or ECG. Electrodes are placed on the chest and each electrical impulse is translated into a wave pattern on a grid. The grid allows for the calculation of the duration and amplitude of each impulse, as well as whether the impulses are abnormal or irregular. Flat lines on the grid represent no electrical activity, upward spikes represent electrical activity or depolarization, and downward spikes represent repolarization.

Specific waves on the ECG grid represent depolarization and repolarization in different parts of the heart. The diagram below shows how each of these waves should normally appear on an ECG grid.

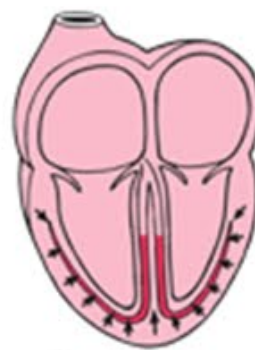- **P wave** – depolarization and contraction of the right and left atria
- **QRS complex** – depolarization and contraction of the right and left ventricles
- **T wave** – repolarization and relaxation of the ventricles
- **PR interval** – time between the depolarization of the atria and the ventricles
- **QT interval** – time for the ventricles to depolarize and repolarize, or contract and relax
- **RR interval** – time for the entire cardiac contraction cycle, based on the ventricles
- **PP interval** – time for the entire cardiac contraction cycle, based on the atria



Activation of the atria



Activation of the ventricles



Recovery wave

http://4.bp.blogspot.com/_5Nslwo9F6bl/S_EU-Kcs4DI/AAAAAAAAAg4/5f0VSazrcN4/s1600/ECG+trace+%26+basics.jpg

Tamarkin, D. 2011. Cardiac Conduction System. STCC Foundation Press, <http://faculty.stcc.edu/AandP/AP/AP2pages/Units18to20/heart/cardiac1.htm>.

Gandelman, G. 2012. Cardiac Conduction System. Medline, National Institutes of Health, www.nlm.nih.gov.

Materials

Computer/internet

Calculator

Interval calipers (optional)

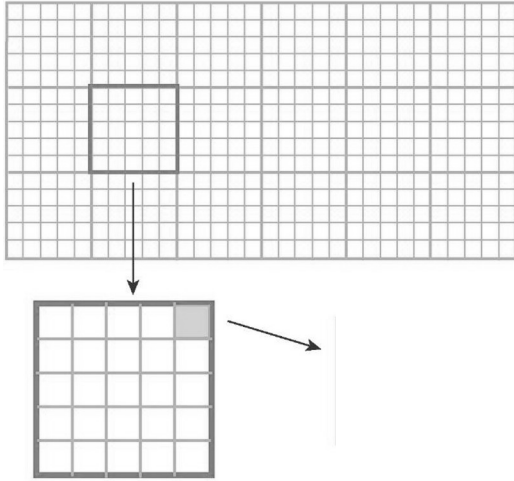

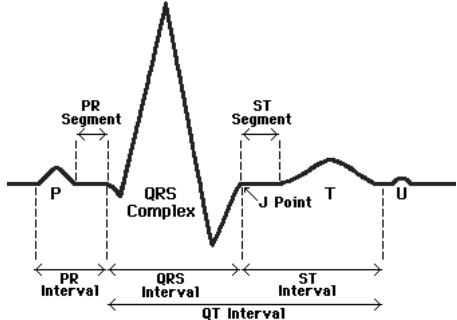
Part A. How to Interpret Electrocardiograms





Use the following online activity to learn how to interpret an electrocardiogram. Record your answers for each question in the space provided.





Go to the following website:

www.practicalclinicalskills.com/ekg.aspx

Scroll down and click on “EKG Basics.” Go through the table of contents on the left side, starting at the top, to answer the following questions and learn how to interpret EKGs.

Table of Contents	Q & A	Diagrams
<p style="text-align: center;">1</p> <p style="text-align: center;">EKG Grid</p>	<p>a. What does the horizontal axis record?</p> <p>b. What marks each second?</p> <p>c. How many seconds is each large block?</p> <p>d. How many seconds is each small block?</p> <p>e. What does the vertical axis record?</p> <p>f. How many millivolts is each small block?</p> <p><i>Record how many seconds and millivolts for each small block in the diagram.</i></p>	 <p>http://what-when-how.com/wp-content/uploads/2012/04/tmp14273_thumb1.jpg</p>
<p style="text-align: center;">2</p> <p style="text-align: center;">EKG Nomenclature</p>	<p>a. What does each waveform component represent?</p> <p><i>Identify the P,Q,R,S,T, and U waves on the diagram.</i></p>	 <p>http://upload.wikimedia.org/wikipedia/commons/thumb/5/55/Qrs.svg/425px-Qrs.svg.png</p>
<p style="text-align: center;">3</p> <p style="text-align: center;">EKG Analysis in 8 Steps</p>	<p>a. What are the 8 steps needed to analyze an EKG?</p>	 <p>http://www.usfca.edu/fac-staff/ritter/Image20.gif</p>

<p style="text-align: center;">4</p> <p style="text-align: center;">Rhythm</p>	<p>a. What measurement can be used to determine whether the ventricular rhythm is regular or irregular?</p> <p>b. What measurement can be used to determine whether the atrial rhythm is regular or irregular?</p> <p><i>Determine whether the R-R and P-P intervals are regular or irregular in the diagram.</i></p>	
<p style="text-align: center;">5</p> <p style="text-align: center;">Heart Rate</p>	<p>a. What is the second method of determining the heart rate?</p> <p>b. If there are 20 boxes between an R-R interval, what is the heart rate?</p> <p><i>Determine the heart rate in the diagram.</i></p>	
<p style="text-align: center;">6</p> <p style="text-align: center;">P Wave</p>	<p>a. What does the P wave represent?</p> <p>b. What is the normal duration and shape of the P wave?</p> <p>c. What are 5 questions that should be asked about a P wave?</p> <p><i>Answer the questions at right for the P waves in the diagram.</i></p>	 <p>Present? _____</p> <p>Regular? _____</p> <p>One P wave for each QRS? _____</p> <p>Smooth, rounded, upright? _____</p> <p>All similar shape? _____</p>
<p style="text-align: center;">7</p> <p style="text-align: center;">PR Interval</p>	<p>a. What does the PR interval indicate?</p> <p>b. How is the PR interval measured?</p> <p>c. What is the normal PR interval for adults?</p> <p><i>Answer the questions about the PR interval in the diagram.</i></p>	 <p>PR interval time: _____</p> <p>Constant: _____</p>

<p style="text-align: center;">8</p> <p style="text-align: center;">QRS Interval</p>	<p>a. What does the QRS complex indicate?</p> <p>b. Why is the QRS complex larger than the P wave?</p> <p>c. How is the QRS interval measured?</p> <p>d. What is the normal duration of the QRS interval?</p> <p><i>Answer the questions for the QRS interval in the diagram.</i></p>	 <p>QRS interval time: _____</p> <p>Similar appearance? _____</p>
<p style="text-align: center;">9</p> <p style="text-align: center;">T Wave</p>	<p>a. What does the T wave represent?</p> <p>b. What is important to note about a T wave?</p> <p>c. How does the U wave appear?</p> <p><i>Answer the questions for the T wave and U wave in the diagram.</i></p>	 <p>Downward or upward? _____</p> <p>U wave appearance? _____</p>
<p style="text-align: center;">10</p> <p style="text-align: center;">QT Interval</p>	<p>a. What does the QT interval represent?</p> <p>b. How is the QT interval measured?</p> <p>c. What is the normal duration of the QT interval?</p> <p><i>Answer the question for the QT interval in the diagram.</i></p>	 <p>QT interval time: _____</p>
<p style="text-align: center;">11</p> <p style="text-align: center;">ST Segment</p>	<p>a. What does the ST segment represent?</p> <p>b. How should the ST segment appear?</p> <p><i>Answer the question for the ST segment in the diagram.</i></p>	 <p>Normal ST segment? _____</p>

Part B. Practice Interpreting Electrocardiograms

Now that you have learned how to interpret an EKG, practice interpreting the EKG samples for the following patients. In the analysis section, determine whether the characteristics of the EKG are normal or abnormal using what you learned in Part A.

Patient A

Rhythm: _____

Heart Rate: _____

P Wave: _____

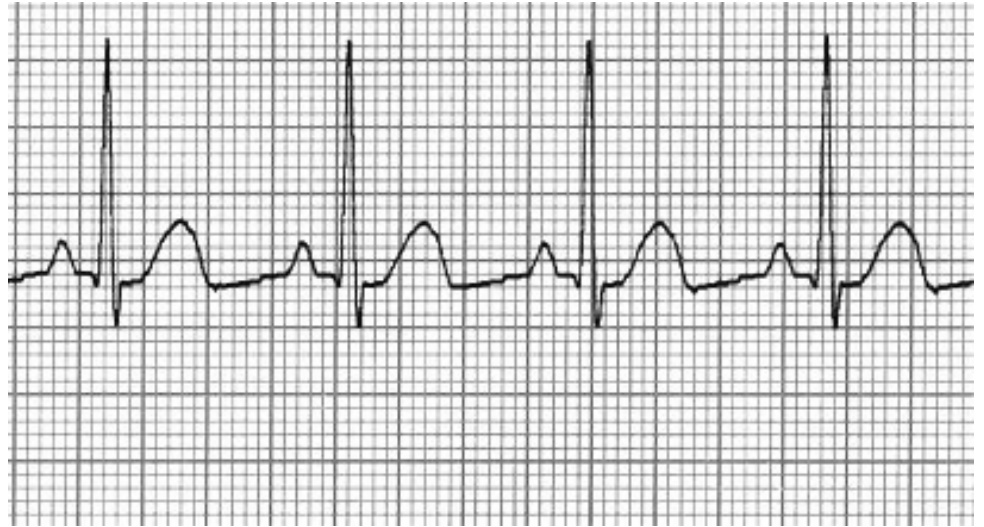
PR Interval: _____

QRS Interval: _____

T Wave: _____

QT Interval: _____

ST Segment: _____



Patient B

Rhythm: _____

Heart Rate: _____

P Wave: _____

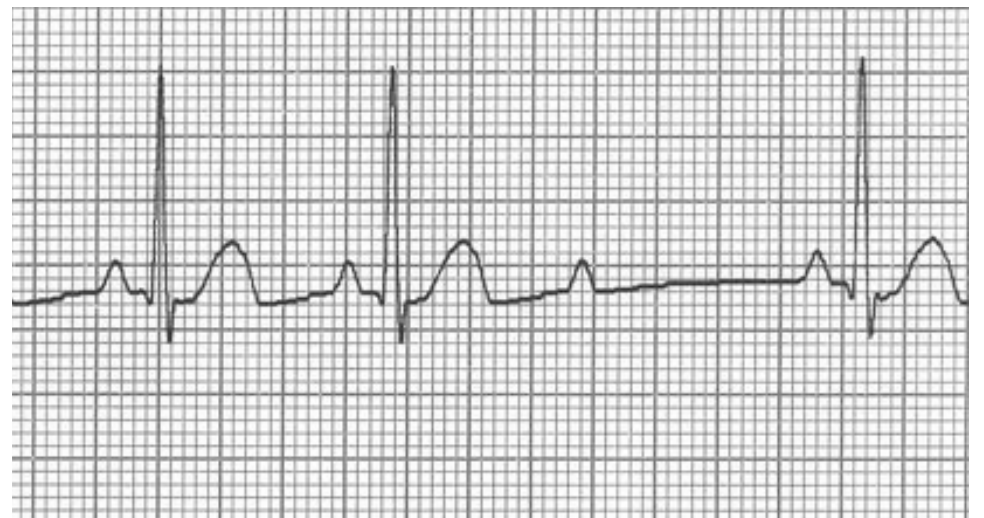
PR Interval: _____

QRS Interval: _____

T Wave: _____

QT Interval: _____

ST Segment: _____



Patient C

Rhythm: _____

Heart Rate: _____

P Wave: _____

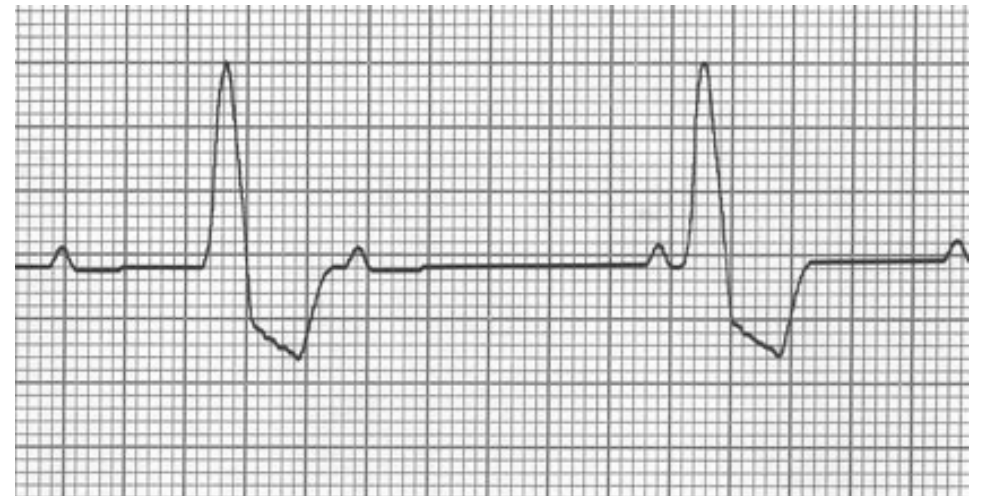
PR Interval: _____

QRS Interval: _____

T Wave: _____

QT Interval: _____

ST Segment: _____



Patient D

Rhythm: _____

Heart Rate: _____

P Wave: _____

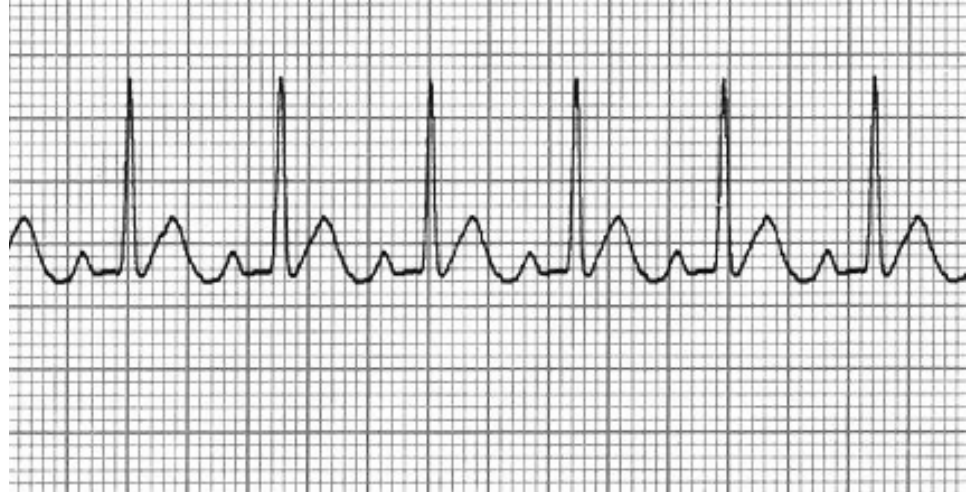PR Interval: _____

QRS Interval: _____

T Wave: _____

QT Interval: _____

ST Segment: _____



Patient E

Rhythm: _____

Heart Rate: _____

P Wave: _____

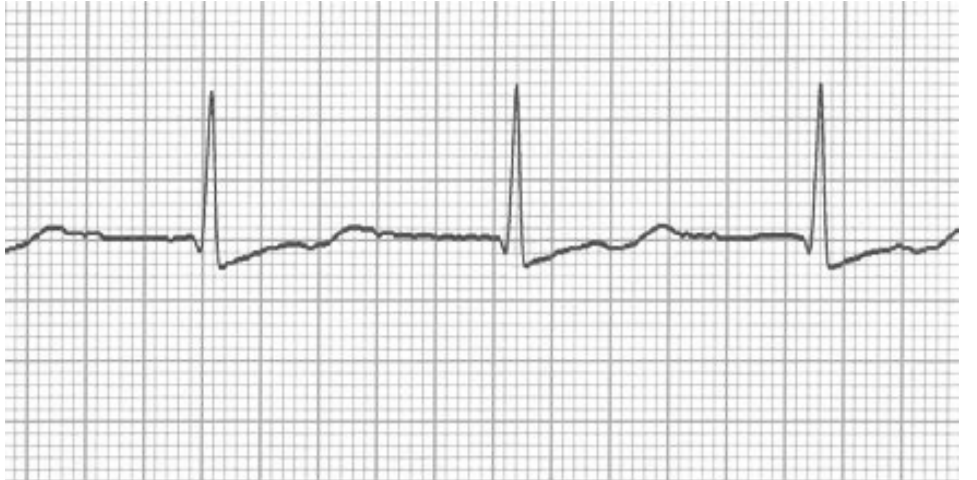PR Interval: _____

QRS Interval: _____

T Wave: _____

QT Interval: _____

ST Segment: _____



Patient F

Rhythm: _____

Heart Rate: _____

P Wave: _____

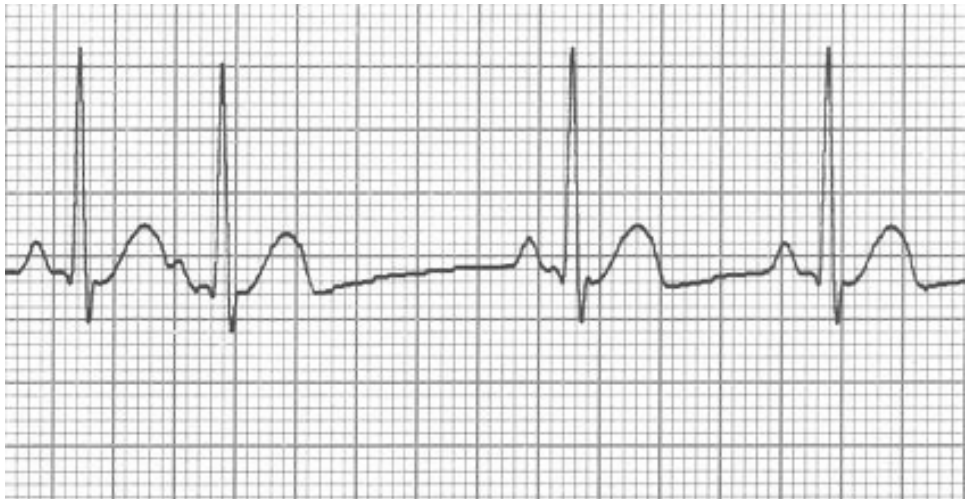
PR Interval: _____

QRS Interval: _____

T Wave: _____

QT Interval: _____

ST Segment: _____



Patient G

Rhythm: _____

Heart Rate: _____

P Wave: _____

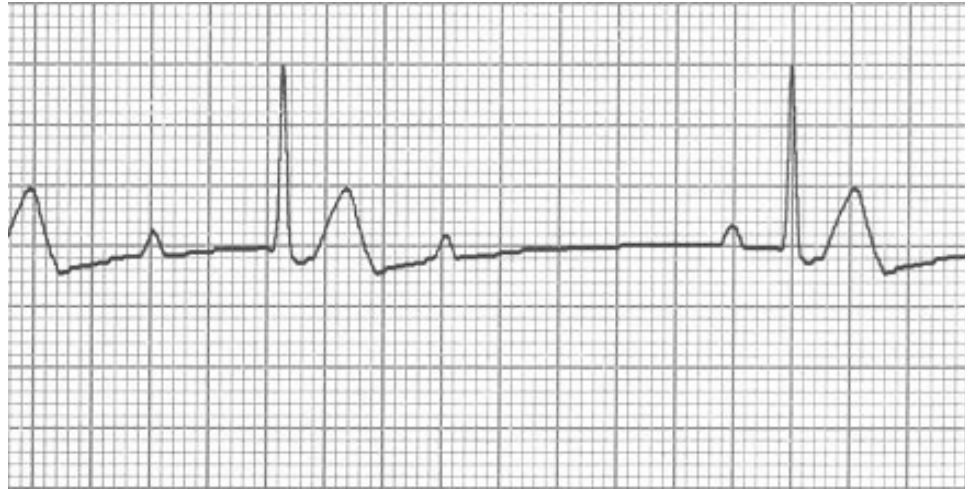PR Interval: _____

QRS Interval: _____

T Wave: _____

QT Interval: _____

ST Segment: _____



Patient H

Rhythm: _____

Heart Rate: _____

P Wave: _____

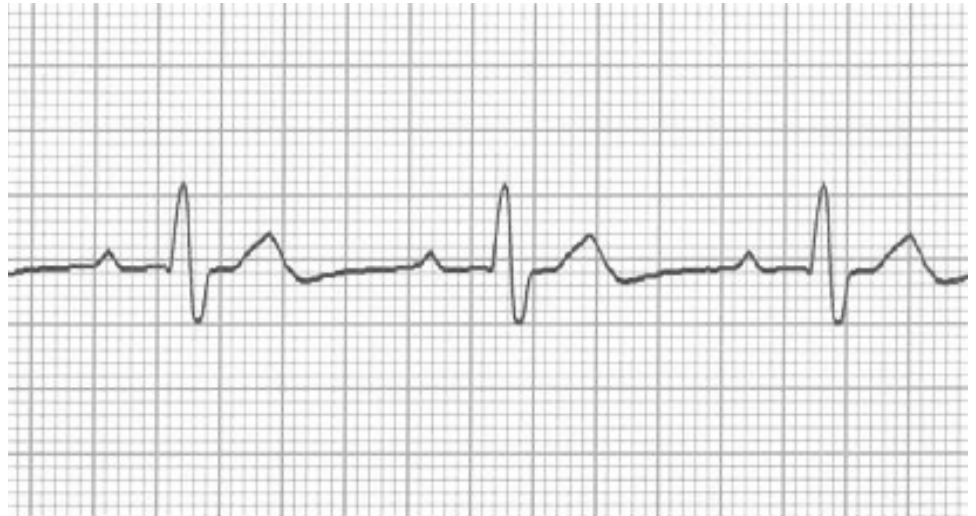
PR Interval: _____

QRS Interval: _____

T Wave: _____

QT Interval: _____

ST Segment: _____



Patient I

Rhythm: _____

Heart Rate: _____

P Wave: _____

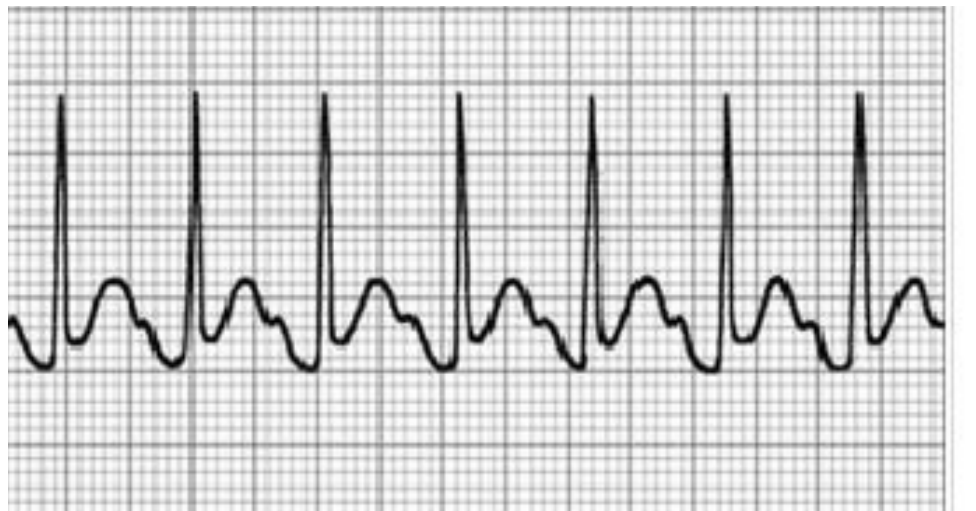PR Interval: _____

QRS Interval: _____

T Wave: _____

QT Interval: _____

ST Segment: _____



Analysis Questions - *on a separate sheet of paper complete the following*

1. For your patients in Part B, compare the results you calculated with the normal values you recorded in Part A. List any abnormal findings that were found in the EKG for EACH patient.

Review Questions - *on a separate sheet of paper complete the following*

1. What is the cardiac conduction system?
2. What are the three crucial parts of the cardiac conduction system?
3. What is the function of the SA node?
4. What is the function of the AV node?
5. What is the function of the His-Purkinje System?
6. Explain how an electrical impulse created in the SA node eventually leads to the contraction of the ventricles.
7. Explain how depolarization and repolarization occur. How do these relate to muscle contraction and relaxation?
8. What is the average number of electrical impulses created by the SA node?
9. What is the sinus rhythm?
10. What could cause the SA node to increase the number of electrical impulses?
11. What is an electrocardiogram?
12. Explain how the up and down motion of the lines on an ECG grid represent the electrical activity of the heart.
13. What does the P wave represent?
14. What does the QRS complex represent?
15. What does the T wave represent?

